



Management of Varicose Eczema through Ayurveda

Saurabh^{1*}, Rakesh RN²

¹Consultant in Shalya Tantra, RK University Ayurvedic College and Hospital Rajkot, India 360020. ²Associate Professor, Dept. of ShalyaTantra, SDM College of Ayurveda and Hospital, Kuthpady, Udupi, India 574118.

Correspondence: *Email: dr.saurabhchaurasia@gmail.com, Mobile: +918495835718

ABSTRACT

Varicose eczema is the condition usually present secondary to varicosity of superficial veins. There is no successful surgery as well as medical remedy available for complete cure of this condition. Contemporary treatment includes combination of locally applied topical steroids and use of emollients either applied directly or via emulsifying oils in bathing water with the treatment of varicose veins, which includes ligation, ligation with stripping, surgical treatments etc. But these treatments can cause re-occurrence. Considering this, alternatives are being searched by the suffering, as well the medical field too. A 38 year old male with complaints of pain, burning and discharges in the medial side of left lower limb associated with dilated and tortuous veins in the anterior aspect of lower leg with discolouration visited the hospital. He was treated with *virechana* (therapeutic purgation), internal medications, external treatments and *siravyadha* (venesection). After the treatment, all the signs and symptoms of varicose eczema as well as varicosity reduced significantly.

KEYWORDS

Siravyadha, varicose eczema, varicose vein, *virechana karma*

Received: 22.12.2016

Accepted: 24.03.2017

DOI: 10.5530/jams.2017.2.1

INTRODUCTION

Varicose eczema^[1] refers to the skin changes that occur in the leg as result of stasis or pooling by gravitational collection of blood from insufficient venous return. The name, varicose eczema comes from a common cause of this being varicose veins. The signs include oedema, hyperpigmentation, venous dermatitis, chronic cellulitis, cutaneous infarction (atrophie-blanche) lipodermatosclerosis, lichenification of the skin of particular limb and ulceration. In developed countries, the most common chronic wounds are leg ulcers. The prevalence of varicose veins increases with age which is in age group 55 to 64 (55.7%).^[2] Venous ulcer commonly develops at around and above the medial malleoli, and medial aspect of lower leg because of presence of large number of perforators which transmit pressure changes directly into superficial system. Ulcer is often large, non-healing, tender and recurrent with secondary infection. It presents with complications of venous diseases like eczema, ulceration, lipodermatosclerosis and venous ulcers.^[3] Sushruta mentioned the non-healing wounds in the similar manner and mentioned the prognosis of that wounds.^[4] The signs of *Dushta Vrana* (chronic wounds) mentioned in the classics are *Ativivrita* (broad based), *Bhairava* (ugly looking), *Putipuyamansa* (purulent pus discharge), *Gandha* (foul smell), *Vedana* (pain), *Dirghakalanubandhi* (chronic in nature).

CASE REPORT

The patient

A 38 years old male patient reported on 24 February 2014 to *shalya tantra* OPD, SDM College of Ayurveda and Hospital, Udupi, Karnataka with complaints of pain, mild itching, burning sensation and discharges from the medial side of left lower limb near ankle joint since 2 months associated with dilated and tortuous veins in the anterior aspect of both lower limbs with discolouration since 10 years.

History of the illness

The patient was apparently normal 10 years back. He noticed slight bulging of veins in the both lower limbs below the knee joints, which he ignored for 3 years, later, he developed discolouration near ankle and foot, associated with itching and burning sensation. He had undergone allopathic treatment for 3 years, but got only temporary relief. Later he was advised for Doppler study of veins and diagnosed as sephano-femoral incompetence and advised surgery, but he was reluctant. Since last two months, pain was aggravating on long standing especially in the evenings and during night hours accompanied with mild swelling, itching and serous discharges from the left ankle region was also there. On examination, there was pain, swelling and dilated tortuous veins in the foreleg as well as in the calf region. There was swelling, and exfoliation of skin with serous discharges in the left ankle region with blackish blue discolouration of the skin. Patient was having regular daily activities except sleep which was disturbed during night due to pain. Patient's occupation was hotel worker so he had to stand for long hours. He was addicted to smoking, generally 5 to 8 cigarettes per day since last 20 years. Patient had no history of diabetic mellitus, hypertension, tuberculosis, venereal diseases, bronchial asthma, anaemia, cardiac diseases and any other major illness.

He did not report any surgical history in past. Routine blood investigations for complete blood count (CBC), blood sugar level, serum creatinine and lipid profile were normal. With these observations the case was diagnosed as varicose eczema and admitted in SDM Ayurveda Hospital, Udupi for further treatments.

The treatment

Considering the history and examination, *Virechana* (Purgation) and *Triphala Kwatha Parisheka*,^[4] dressing with *Jatyadi taila*^[5] over local site were planned. Later, *Siravyadha* (Venesection) was done to remove vitiated and stagnated blood. Patient was administered with *Chitrakadi vati* 450 mg 2 tid^[6] before food for two days for *Deepana and Pachana* (Digestive and Assimilative function). After two days, patient has attained *Samyak Pachana Lakshana*^[7] (Proper digestive function) and then he was posted for *Snehapana* (Internal Administration of Medicated Clarified butter) with *Mahatiktaka Ghrita*^[8] for 5 consecutive days (till *Samyak Snigdha Lakshana*) with initial dosage of 30 ml increasing to 60, 100, 140, and 240 ml on second, third, fourth and fifth days respectively followed by *Sarwanga Abhyanga* (External body massage) with *Balaguduchyadi Taila*^[9] and then *Sarwanga Swedana* (Sudation therapy) was performed for next 3 days. On 3rd day of *Sarwanga Abhyanga* and *Swedana*; patient was administered with 50 gm of *Trivrut Lehyam*^[10] for *Virechana* along with *Drakshadi kashayam* as *Anupaana* (vehicle). Patient had 16 *Vega* (purgation) with *Kaphanta* (Ending with phelgam) and attained *Madhyama Shudhi* (Moderate purification).^[11] Patient was observed for complications throughout the day. Later patient was advised to follow *Samsarjana Karma* (Therapeutic dietary regimen) for 5 days, after which, *Raktamokshana* (Bloodletting) in the form of *Siravyadha* to remove *dooshita rakta* (Vitiated blood) was performed.

Poorvakarma (pre-operative procedure) for *Siravyadha*: Gauze piece, swabs, bandages, tourniquet, kidney trays, ounce glass, beaker, scalp vein (no. 20), spirit, chairs and dressing table were kept ready for the procedure. Leg to be punctured was flexed and a tourniquet was tied just above the calf region to visualize the veins carefully after *Abhyanga* (localized oil massage) and *Swedana* (fomentation).

Pradhana karma (Main procedure): Most tortuous vein was selected and punctured with no. 20 scalp vein set (butterfly cannula), blood was allowed to flow into a beaker. During this procedure, total 200 ml blood was drained out. *Siravyadha* was done till blood flow was stopped by itself.^[12]

Paschat karma (post-operative procedure): When the flow of the blood was ceased, the needle was withdrawn. The area was cleaned with cotton swab and tight bandaging was done with *Yastimadhu ghrita*.^[13] Later patient was advised rest by keeping his legs raised with the help of a pillow. Internally patient was administered with *Kaishor guggulu* - 450 mg tablets 1tid^[9] *Guru rasayana* (*Shilajatu Loha Rasayana*)^[14] 500 mg capsules 2 tid and *Mahamanjistadi quath*^[9] 4 tsp bd after food. This was continued in follow up period and he was advice to review at every 15 days; avoidance of prolonged standing, calf muscle strengthen exercise (bicycle riding in the air while lying on back), avoidance of oily and spicy food, sour items bakery items, curd, excessive sweets etc were advised.

There was relief in the signs and symptoms during the treatment course. The results obtained after the external treatments and internal medication was encouraging. Pain, swelling, burning sensation were reduced considerably. Dilated and tortuous veins in the lower leg have reduced. Bluish discolouration present in the dilated veins was reduced (Table 1 and Figure 1).

Table 1. Grading different symptoms before and after treatment

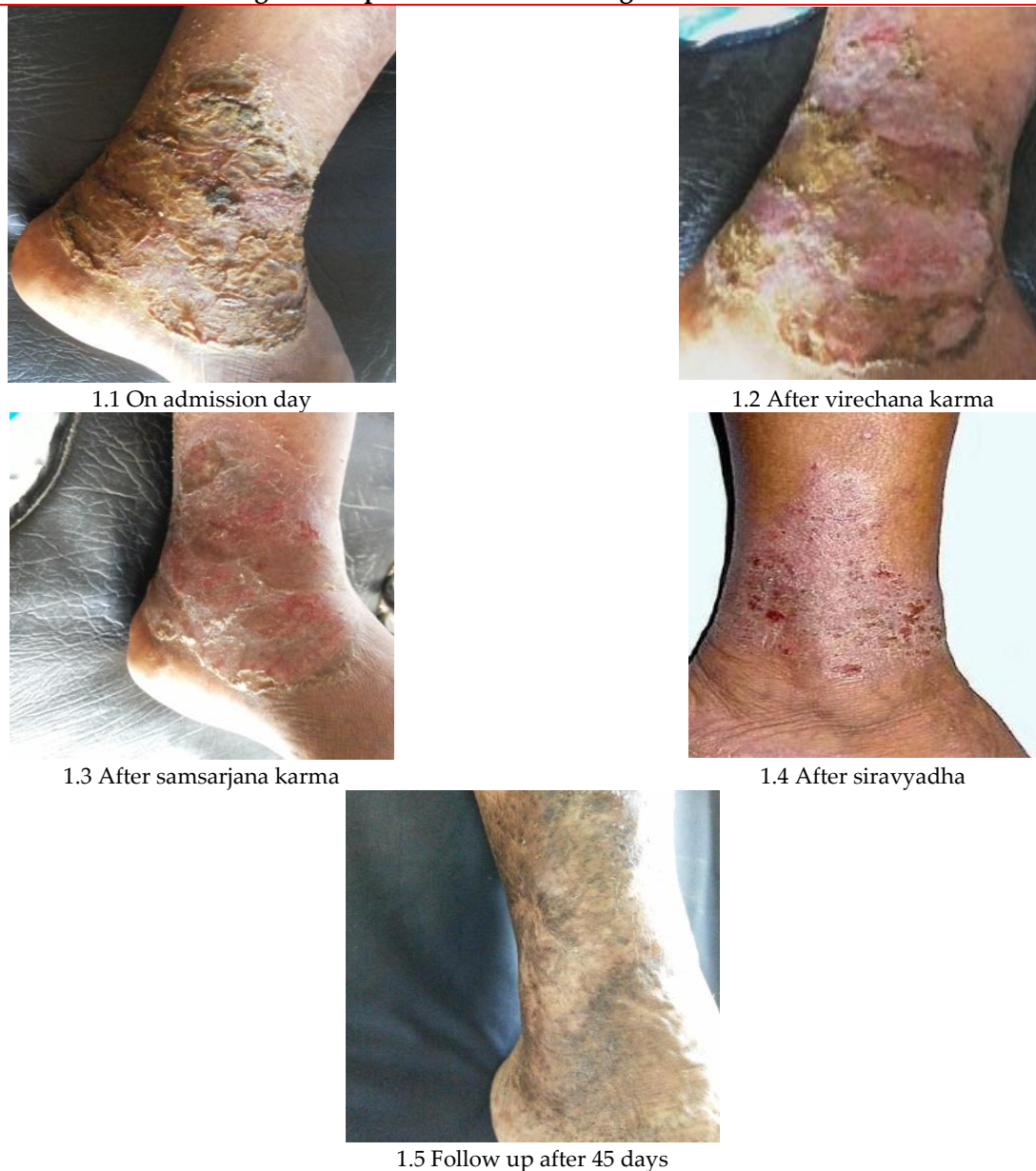
Symptoms	Before treatment	After virechana	After samsarjana	After siravyadha	Follow up (after 45 days)
Pain	+++	++	+	+	-
Tenderness	Grade 3	Grade 2	Grade 2	Grade 1	Absent
Discharges	+++	++	+	-	-
Burning sensation	++++	+++	++	+	-
Discolouration	++++	++	++	++	++
Eczematous changes	++++	++	++	+	-
Varicosity	Present	Present	Present	Present	Present

DISCUSSION

Patient had presented with symptoms of pricking pain (due to exacerbated *Vata* and *Pitta*), dilated torturous veins (*Sira*, the *upadhatu* of *Rakta*) in both the legs below knee joints and local skin changes (due to vitiated *Vata*, *Pitta*, *Rakta* and *Mamsa*).^[15] Treatment was planned based on principle that chronic diseases require some form of *Shodhana* (systemic purification). In this condition, *Vrana* and *vata rakta* line of treatment was adopted i.e. *Avasechana* (Purificatory measures) as per *Doshik* involvement. Accordingly, *Virechana karma* to eliminate vitiated *Pitta* and *Rakta Dosha* and *Vata Anulomana* (Passage of flatus) was planned. *Siravyadh* is the treatment of choice prescribed by the classics for *Siragranthi* (varicose vein). *Virechana* along with local care, *Shamana aushadhi* and *Rakta moksha* have shown remarkable healing response in this patient. In the course of treatment *deepana* and *pachana dravyas* were administered for the correction of *agni* (Digestive fire). *Maha Tiktaka Gritha* was selected for *Snehapana* as it is indicated in *Pitta vikara*, *Ruk*, *Twak vikara* and *Vrana*. The accumulation of vitiated *Rakta* (blood) and *vata* in *Siras* (veins) leads to dilation and tortuous veins. *Siravyadham* brings down the local *Shotha* (swelling) and congestion. This promotes proper

circulation, where stasis is cleared off. It is stated that when *rakta* flows out of the body, at the beginning only *dushtarakta* flows out and after that only, *shuddharakta* comes out of the body. *Raktamokshan* or bloodletting is known to reduce inflammation. It removes the inflammatory mediators such as tumor necrosis factor- α , interleukin-1 β , interleukin-6 and interleukin-22 from the blood stream and thus can control eczematous reactions effectively.^[16] During the treatment, *Daha* (burning sensation), a feature of *Pitta* is completely relieved that might be due to reduced localised intravascular pressure. Tortuosity was partially relieved may be due to regaining of normal elasticity by external punctures and the expulsion of static blood.

Figure 1 Improvement seen during treatment course



CONCLUSION

Virechanakarma, *Siravyadham* along with internal medications and local care of eczematous part resulted in the reduction of signs and symptoms of varicose eczema as well as *Siragranthi* (varicose veins) specially the symptoms like *Shoola* (pain), *Daha* (burning sensation), *Vaivarnya* (discolouration) and exfoliations of skin. During the follow up period, there was no aggravation in the disease and varicose eczema was completely cured after a period of 45 days. The treatments employed were purely based on the principles of *Ayurveda* and was found to be very effective. The condition of the patient improved remarkably. This line of treatment can be suggested as an effective therapy for the patients suffering from varicose eczema.

ACKNOWLEDGEMENT

I express my deepest gratitude to Dr. Muralidhara Sharma (Medical superintendent), SDM Ayurveda Hospital, Kuthpady, Udipi Karnataka for valuable suggestions and ideas during this case study.

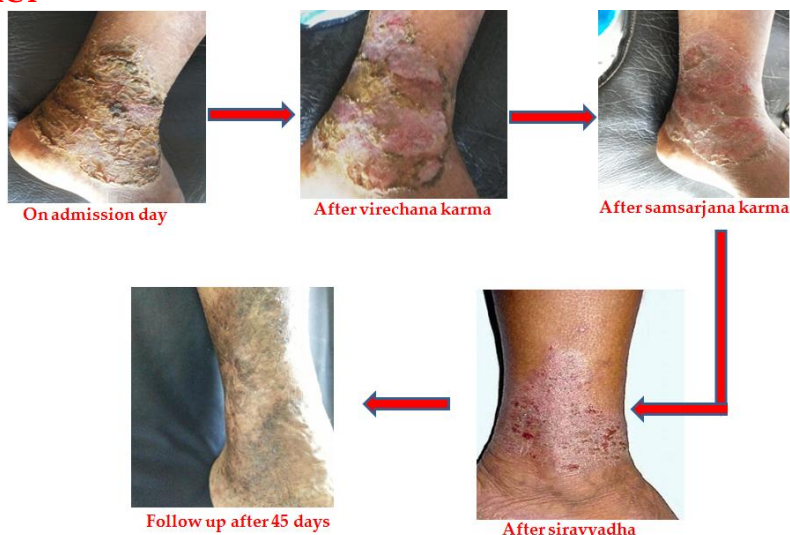REFERENCES

1. Rapini Ronald P, Bologna Jean L, Jorizzo Joseph L. Dermatology, Vol 2, Chapter 14. St. Louis: Mosby; 2007.
2. Dooms-Goossens A, Degreef H, Parijs M, Maertens M. A retrospective study of patch test results from 163 patients with stasis dermatitis or leg ulcers. II Retesting of 50 patients. Dermatologica 1979;159(3):231-8.
3. Raju S, Neglén P. Clinical practice. Chronic venous insufficiency and varicose veins. N Engl J Med 2009;360(22):2319-27.
4. Yadavji Trikamji, Editor. Susruta Samhita Chikitsasthana 1, Sloka 17, commentary by Dalhana Nibandhasamgraha, 9th Ed. Delhi: Chaukhamba Sanskrita Pratisthana; 2007; p.399.
5. Ambikadatha Shastri, Editor. Bhaishajya Ratnavali, Chikitsasthana 47, Sloka 64-69, Kaviraj Shri Govindadas Sen. Delhi: Chaukhamba Subharti Prakashana; 2010; p.597.
6. Yadavji Trikamji, Editor. Charaka Samhita, Chikitsasthana 15, Sloka 96-7, Ayurvedadipika commentary of Chakrapaanidatta. Varanasi: Chaukhamba Orientalia; 2011; p.520.
7. Yadavji Trikamji, Editor. Charaka Samhita, Sutrasthana 15, Sloka 6, Ayurvedadipika commentary of Chakrapaanidatta. Varanasi: Chaukhamba Orientalia; 2011; p.622.
8. Yadavji Trikamji, Editor. Charaka Samhita, Chikitsasthana 7, Sloka 144-50, Ayurvedadipika commentary of Chakrapaanidatta. Varanasi: Chaukhamba Orientalia; 2011; p.622.
9. Nishteswar K, Vidyanath R. Sahasrayogam, Taila Prakarana 11. Varanasi: Chaukhamba Sanskrit Series Office; 2008; p.116.
10. Yadavji Trikamji, Editor. Charaka Samhita, Chikitsasthana 29, Sloka 158-9, Ayurvedadipika commentary of Chakrapaanidatta. Varanasi: Chaukhamba Orientalia; 2011; p.421.
11. Brahmanand Tripathi. Ashtanga Hridayam by Vagbhata, Sutrasthana 18, Sloka 29. Delhi: Chaukhamba Sanskrit Pratishthan; 2015; p.269
12. Yadavji Trikamji, Editor. Susruta Samhita Sharirasthana, 8th Ed. Varanasi: Chaukhamba Orientalia; 2002; p.297.
13. Ambikadatha Shastri, Editor. Bhaishajya Ratnavali, Chikitsasthana 47, Sloka 49, Kaviraj Shri Govindadas Sen. Delhi: Chaukhamba Subharti Prakashana; 2010; p.594.
14. Yadavji Trikamji, Editor. Charaka Samhita, Chikitsasthana 29, Sloka 158-9, Ayurvedadipika commentary of Chakrapaanidatta. Varanasi: Chaukhamba Orientalia; 2011; p.446.
15. Brahmanand Tripathi. Ashtanga Hridayam by Vagbhata, Sutrasthana 18, Sloka 29. Delhi: Chaukhamba Sanskrit Pratishthan; 2015; p.783
16. Abbade LP, Lastória S. Venous ulcer: epidemiology, physiopathology, diagnosis and treatment. Int J Dermatol 2005;44(6):449-56.

ABOUT FIRST/CORRESPONDING AUTHOR

Dr. Saurabh M.S (Ayu) has completed post graduation in Shalyatantra from SDM Ayurveda College and Hospital Udupi, Karnataka in 2016 with first class. He won 1st prize in zonal level Ayurwhiz -2, the national level quiz contest in 2013 at Himalayan Herbal Health care campus Makali Bangalore to represent South India in national level final, 3rd prize at national final of Ayurwhiz-2 held at JN Tata Auditorium Indian Institute of Science, Bangalore on 28th June 2013, conducted by Himalaya herbal health care. He was awarded "Mannam Memorial Award" for state level essay competition by Mannam Ayurveda co-operative medical college Pandalam, Kerala. He won first prize in national Ayurveda essay competition conducted by Vishwa Ayurveda Parishad in three consecutive years 2014, 2015, 2016. Also awarded 1st prize for best case presentation on "Amyotropic Lateral Sclerosis And Ayurveda" at Amrita school of Ayurveda, Amrita Vishwavidyapeetham Kerala. Presented paper at 1st International conference on Advances in Asian Medicine 2016 at Pune and Global Ayurveda Festival, Kochi Kerala 2014.

GRAPHICAL ABSTRACT



Cite this article as: Saurabh, Rakesh RN. Management of Varicose Eczema through Ayurveda. J Ayu Med Sci 2017;2(1):144-7. DOI: 10.5530/jams.2017.2.1



©Journal of Ayurveda Medical Sciences
– Herbal Research Guidance and Solutions' (HRGS) Ayurveda Journal