

ISSN 24564990

J Ayu Med Sc

Quarterly
Journal for
Rapid
Publication
of Researches
in Ayurveda
and Other
Traditional
Medicine



Journal of Ayurveda Medical Sciences

J Ayu Med Sci | 208 | Vol 3 | Issue 1 (Jan . Mar)

www.jayumedsci.com
©Journal of Ayurveda Medical Science

Anti-secretory and Acid Neutralizing Effect of Shankha Draavaka in Albino Rats

Parthipan Nirmala Kuppusamy, Ravindra Angadi^{1*}

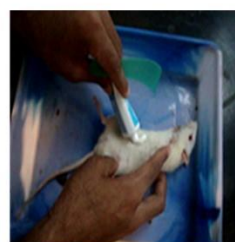Muhurtham Integrated Health Clinic, Ramanathapuram, Coimbatore 641045. ¹Department of Rasashastra and Bhaishajya Kalpana, SDM College of Ayurveda, Kuthpady, Udipi 574118, India.

ABSTRACT

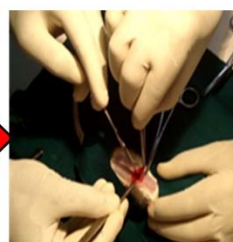
Introduction: Shankha draavaka is a unique preparation explained in classics for *ashtavidhashoola* (eight types of shoola), *agnimandya* (anorexia) and *grahaniroga* (sprue). It is widely indicated in all types of shoola i.e. *shoolam-ashtavidham-hanthi* (alleviates eight types of pains). The two prominent indications of shankha draavaka are *annadravashoola* and *udarashoola*. They are usually co-related with gastritis and colic pains respectively. These two complaints are quite common in day today practice. Taking into account, these two prominent indications of shanka draavaka, this research work was taken up to revalidate the medicinal effects of shankha draavaka. **Methods:** With a motto to assess anti-secretory and acid neutralizing effect of shankha draavaka the experimental study was taken up. In the beginning, the selected albino rats were categorized into 3 groups viz. control group (fed with distilled water), standard group (administered with ranitidine, the standard drug) and test group (administered with shankha draavaka 0.054 ml / 200 g body weight). **Results:** The results suggested that the test drug possessed anti secretory and acid neutralizing effect. **Conclusion:** The study concludes that shankha draavaka possess alkaline property (pH-9.65) and exhibits anti secretory and acid neutralizing effect in acidic environment of gastrium.

KEYWORDS Annadravashoola, Colic pain, Gastritis, Shankhadraavaka, Udarashoola.

PICTORIAL ABSTRACT



Anaesthetizing



Pyloric ligation



Gastric content centrifuged



Gastric content analysis

ARTICLE HISTORY Received 29.03.2018 Accepted 14.04.2018

CORRESPONDENCE Dr. Ravindra Angadi, Associate Professor, S. D. M. College of Ayurveda, Kuthpady, Udipi 574118, India. Email: drraviangadi@gmail.com

CITE THIS RESEARCH AS Parthipan NK, Angadi R. Anti-Secretory And Ulcer Protective Effect of Shankha Draavaka in Albino Rats. J Ayu Med Sci 2018;3(1):337-9.

DOI 10.5530/jams.2018.3.6

The medicine chosen for the study is *shanka draavaka* (*prathama*) from the classical book *Rasa tarangini*^[1]. It is indicated in *annadrava shoola* (gastritis) and *udara shola* (colic pains). This medicine comes with ingredients such as *Shuddha shankha* (conch shell), *Tankana* (borax), *Sphatika* (potash alum), *Yava kshara* (potassium carbonate), *Svarji kshara* (sodium bicarbonate), *Navasaadara* (ammonium chloride), *Saindhava lavana* (sodi chloridum), *Samudra lavana* (sodi muras), *Vida lavana* (black salt), *Souvarchala lavana* (unaqua sodium chloride), and *Romaka lavana* (lake salt). Though *shanka draavaka* is a prominent classical formulation; in easily administrable liquid form with a dosage range of 5 to 16 drops in humans, presently no pharmaceutical company is manufacturing and marketing it. Perhaps it is because of less demand from the practitioners of Ayurveda. To make the formulation more practitioner user friendly, revalidation of its scientific base is necessary.

Kshareeya dravya and *lavana dravya* that feature in *shankha draavaka*, find either direct or indirect references in *Charaka Samhita*^[2], *Sushruta Samhita*^[3], *Ashtanga Hridaya*^[4], *Dhanvantari Nighantu*^[5], *Raja Nighantu*^[6] and *Bhaishajya ratnavali*^[7]. From *Rasa tarangini*. Gastro-intestinal ailments, such as gastritis (*annadrava*

shoola) and colic pain (*udara shoola*), which are the primary indications of *shanka draavaka* are seen more in this era of stressful life and jumbled food habits. Thus, an attempt is made in this study to assess the anti-secretory and acid neutralizing effect of *shanka draavaka* through animal model (pyloric ligation- induced acid secretion and ulcer formation) studies anti-secretory and acid neutralizing.

The raw drug procurement and the pharmaceutical preparation of the test drug i.e. *shanka draavaka* were carried out in SDM Ayurveda Pharmacy Udipi, a GMP certified pharmacy.

As a part of experimental study^[8], after due written approval from the Institutional Animal Ethical Committee formulated in the SDM Center for Research in Ayurveda and Allied Sciences, Udipi, the experimental animals were obtained from Animal house attached to the Pharmacology laboratory. The Ranitidine tablets were used as the standard drug in the dosage of 15 mgs / kg body weight that ranges in between 3 to 3.75 mgs. Inj. Ketamin hydrochloride, NaOH (0.01N), Topfers reagent and collodion were used for anaesthetizing the rats. The equipment used were dissecting microscope, pH strips, burette and surgical equipment.

Animal used were *Wistar* albino rats of either sex not less than eight weeks old weighing in between 150-200 gms; and on the last day of experiment, the animals were fasted for 24 hours (but had free access to water *ad libitum*). They were maintained in the animal house in their habitat at standard conditions. The Shays Method by pyloric ligation^[9] was followed in the experiment. The Albino rats were divided into 3 groups as control, standard and test drug group with six rats in each. In first group distilled water was administered *ad libitum* for first five days & only water on 6th & 7th day to observe the changes occurring in the gastric mucosa. For second group, ranitidine was powdered, diluted with water and administered (15 mgs/kg body weight, ranging in between 3 to 3.75 mgs)^[10] for first five days & only water on 6th & 7th day to observe anti-secretory and acid neutralizing effects. And for the third group the test drug *shanka draavaka* was administered for first five days & only water on 6th and 7th day to observe gastric ulcer preventive activity.

Duration of experimental study was six days housing and seven days experiment that became a total of thirteen days. Dose fixation was done with standard dose conversion formula i.e. Human dose $\times 0.018 \times 5 / \text{Kg body weight}$. Standard drug dose i.e. rat dose i.e. 300 mg $\times 0.018 \times 5 / \text{Kg body weight}$; i.e. 27 mg $\times 0.018 \times 5 / \text{Kg body weight}$; and that becomes 5.4 mg / 200 g body weight. Test drug dose will be Rat dose i.e. 3 ml $\times 0.018 \times 5 / \text{Kg body weight}$; i.e. 0.27 ml / Kg body weight; and that becomes 0.054 ml / 200 g body weight. Standard rat dose of standard drugs ranitidine was 15 mg/kg body weight that ranged in between 3 to 3.75 mgs.

On 6th and 7th day along with fasting (but had free access to water *ad libitum*) the standard drug and the trial drug were administered to the respective groups. The fasted rats were anaesthetized with 0.5 cc of ketamin hydrochloride injection.

The rat was secured on the operating table. An incision of 1 cm long in the abdomen just below the sternum was given. The stomach was exposed. A thread was passed around the pyloric sphincter and a tight knot was applied. Care was taken while putting the knot, in such a way that no blood vessel is tied along the knot. The abdomen wall was closed by putting the sutures. The skin was cleaned from any blood spots and bleeding. Collodion was applied over the wound. Then the rat was kept in a separate cage and allowed to recover. For the standard and trial group after 1 hour of administration of respective drugs, pyloric ligation was done as described earlier. After 4 hours of pyloric ligation the animals were sacrificed by inhalation of chloroform.

The abdomen was opened and esophageal end (cardiac end) of the stomach was tied. The entire stomach was Cut and removed from the body of the animal. A small cut was given to the pyloric region just above the knot and the contents of the stomach were collected in a graduated centrifuge tube. The stomach was opened along the greater curvature and washed slowly under the running tap water. It was put on the slide glass and observed for ulcers. Later it was preserved in 10% formalin solution.

The gastric content was centrifuged at 1,000 rpm for 10 min. The volume was noted. 1 ml of the supernatant liquid was Pipette out and diluted with 10ml distilled water. pH of this solution was noted with the help of pH strip. The solution was titrated against 0.01N sodium hydroxide using Toppers reagent (it is dimethyl-amino-azo-benzene with phenolphthalein and used for detection and estimation of hydrochloric acid and total acidity in gastric fluids) as indicator.

It was observed that the activity and food consumption of control group and trial group rats were normal throughout the study. The activity and food consumption of standard group rats were reduced

from second day of the study. All the surgical procedures were done normally and the animals recovered normally. Rat-6 of trial group showed more mucus in the gastric secretion, which was atypical in relation to other group. Ulcer index study showed that the gastric mucosa of all group rats appeared very normal pink color. There were no signs of reddish discoloration (indicating inflammatory changes), blood streaks or ulceration spots.

From the second day of the study, mild reduction in the food consumption and activity in the standard group rats was observed and this was progressing. This could be due to the H₂-blocking activity of the standard drug i.e. ranitidine.

When the gastric juice analysis was done, the anti-secretory property of trial drug was validated with its mean volume (1.6 ml), in relation to the control group mean volume (2.6 ml). The anti-secretory property of trial group could be equally potent to that of standard group. This was assessed by comparing the mean volume of gastric juice of both the groups. The acid neutralizing property of the trial drug could be inferred by its mean pH (6.1) to that of the control group (4.5) and standard group (6.1) (Table 1).

Table 1. Effect of *Shankha draavaka* on gastric juice

	Volume in ml	pH
Control Group	2.6	4.5
Ranitidine hydrochloride	1.5	6.1
<i>Shankha draavaka</i>	1.6	6.1

The probable reason for the absence of ulcer formation in all the three groups could be due to insufficient time period provided after pyloric ligation or coprophagy. The probable mode of action of *shankha draavaka* could be due to its strong alkaline properties (pH-9.65) of the drug *shankha* and its other ingredients in it. As per classical opinion *shankha* is good in controlling the heartburn, sour eructation, pain in abdomen and indigestion, it is especially useful when increased stomach acid causes pain in stomach or intestine.

Shankha is a good source of calcium, which is an essential component in the production of various enzymes and hormones that regulates digestion. Insufficient presence of calcium can cause low pH, which in long term can cause chronic acidosis^[11]. *Shankha* mainly consists of calcium, iron and magnesium and is well known for its acid neutralizing effects^[12].

Shankha draavaka possesses alkaline property. Its pH is 9.65. The experimental study reveals that *shankha draavaka* evidently exhibits anti secretory as well as acid neutralizing effects. Thus, when used judiciously, this medicine can be a useful medicine in cases of *annadravashoola* (gastritis) and *udarashool* (colic pain).

Acknowledgement Mr. Ravi Mundugaru is acknowledged for animal experiments and data analysis. Dr. KN Sunil Kumar is acknowledged for contribution to the intellectual content of study design and manuscript review. Authors thank Dr. Rekha Jambunathan for edition of the research paper.

Source of support Nil

Conflict of interest None declared

Contributors Dr. Ravindra Angadi contributed to the conceptualization of the topic and manuscript editing. Dr. Nirmala Kuppusamy Parthipan and Dr. Ravindra Angadi contributed to study design, literature study, data acquisition and study conduction.

References

1. Sharma S, editor, (1st ed.). Rasatarangini of Sadananda Sharma, Transcendence English Commentary of Ravindra Angadi, Chapter 12, Verse 40-42, Varanasi, Chaukhamba Surabharati Prakashan series, 2015; p 196.
2. Agnivesha, editor, (revised 1st ed.). Charaka Samhita, Ayurveda deepika commentary by Yadvi Trikamji vaidya, Chikitsa sthana, Chapter 12, Verse 167, Varanasi, Chaukhamba Surabharati Prakashan series, 2008; p 499.
3. Sushruta, editor, (revised 1st ed.). Sushruta Samhita, Nibandha sangraha commentary by Dalhanacarya, Chikitsa sthana, Chapter 13, Verse 10, Varanasi, Chaukhamba Surabharati Prakashan series, 2008; p 459.
4. Vagbhata, editor, (revised 1st ed.). Ashtangahrudaya, Sarvangasundara of Arunadatta and Ayurveda Rasayana of Hemadri commentary, Chapter 15, Verse 86-87, Varanasi, Chaukhamba Surabharati Prakashan series, 2007; p 698.
5. Bhogika Mahendra, (1st ed.). Dhanvantari nighantu, Hindi Commentary by P V Sharma, Guruprasad Sharma, Varanasi, Chaukhamba Krishnadas Academy, 2001; p 119.
6. Narahari, (1st ed.). Rajanighantu, edited with Hindi commentary by Indradev Tripathi, Varanasi, Chaukhamba Krishnadas Academy, 2001; p 452.
7. Das Govind, (1st ed.). Bhaishajya Ratnavali, Sidhiprada Hindi Commentary by Sidhinanadana Mishra, Varanasi, Chaukhamba Surabharati Prakashan, 2015; p 1195.
8. Gosh MN, (3rd ed.). Fundamentals of Experimental Pharmacology; Hilton & company, Kolkata, 2005.
9. Kulkarni SK, (3rd ed.). Hand book of experiential pharmacology; Vallabh Prakashan, New Delhi, 2012; p 148.
10. Patil AN, Advani MG, Mali SN, Pawar S, Raut SB. Evaluation of anti-ulcer effect of amlodipine in gastric ulcer models in rats. Indian Journal of Pharmacology 2012;44(3): 387-89.
11. Crampton L. Hydrochloric Acid in the Stomach and Digestive Problems; <https://owlcation.com/stem/Hydrochloric-Acid-in-the-Stomach-and-Digestive-Problems>.
12. Internal Clinical Guidelines Team (UK), Dyspepsia and Gastro-Oesophageal Reflux Disease: Investigation and Management of Dyspepsia, Symptoms Suggestive of Gastro-Oesophageal Reflux Disease, or Both. London: National Institute for Health and Care Excellence (UK); 2014 Sep.